



ORIGINAL ARTICLE

Epithelium-Off vs. transepithelial corneal collagen crosslinking in progressive keratoconus: 3 years of follow-up



Ángeles Arance-Gil^a, César Villa-Collar^{a,b,*}, Belén Pérez-Sánchez^c, Gonzalo Carracedo^d, Ramón Gutiérrez-Ortega^a

^a Clínica Novovisión, Madrid, Spain

^b Department of Pharmacy, Biotechnology, Nutrition, Optics and Optometry, Faculty of Biomedical and Health Sciences, European University of Madrid, Madrid, Spain

^c Department of Statistics, Mathematics and Informatics, Miguel Hernández University, Elche, Spain

^d Department of Optometry and Vision, Faculty of Optic and Optometry, Complutense University of Madrid, Madrid, Spain

Received 25 November 2019; accepted 15 July 2020

Available online 1 September 2020

KEYWORDS

Collagen crosslinking;
Epithelium-Off
collagen crosslinking;
Transepithelial
collagen crosslinking;
Progressive
keratoconus

Abstract

Purpose: To compare the efficacy of epithelium-off corneal collagen crosslinking (CXL) with transepithelial CXL in patients with progressive keratoconus with a follow-up of 3 years, taking into account the patients' age and the location of the corneal ectasia.

Methods: In this prospective study participated 64 eyes with progressive keratoconus were included in this long-term study, of which 31 eyes were treated by epithelium-off CXL and 33 by transepithelial CXL. All of the patients with a follow-up of 36 months were evaluated for visual variables (corrected distance visual acuity (CDVA), corneal aberrations, and corneal densitometry), structure variables (astigmatism, keratometry, corneal asphericity, maximum posterior elevation, corneal thickness, and corneal volume), and keratoconus index variables.

Results: After corneal CXL, CDVA improved significantly in both central and paracentral keratoconus, with greater improvement in the centrals ($p=0.001$), asphericity at 6 mm improved in central keratoconus ($p=0.047$). In the epi-off group, there was a significant improvement in coma-like ($p=0.038$), higher-order aberrations ($p=0.036$), asphericity at 8 mm ($p=0.049$), asphericity at 10 mm ($p=0.049$), and index of surface variance ($p=0.049$).

* Corresponding author.

E-mail addresses: gelesarance@hotmail.com (Á. Arance-Gil), cesar.villa@universidadeuropea.es (C. Villa-Collar), belen@ua.es (B. Pérez-Sánchez), jgcarrac@ucm.es (G. Carracedo), ramon@clinicaramongutierrez.com (R. Gutiérrez-Ortega).

<https://doi.org/10.1016/j.optom.2020.07.005>

1888-4296/© 2020 Spanish General Council of Optometry. Published by Elsevier España, S.L.U. This is an open access article under the CC BY-NC-ND license (<http://creativecommons.org/licenses/by-nc-nd/4.0/>).

Conclusion: Although both techniques halted and stabilized the progression of keratoconus, epithelium-off CXL was more effective. In addition, after the corneal CXL, there was a greater degree of regularization of the corneal surface and, therefore, a greater improvement in the CDVA with central keratoconus than with paracentral keratoconus.

© 2020 Spanish General Council of Optometry. Published by Elsevier España, S.L.U. This is an open access article under the CC BY-NC-ND license (<http://creativecommons.org/licenses/by-nc-nd/4.0/>).

Introduction

Keratoconus (KC) is a bilateral and generally asymmetric ectopic corneal disorder that induces a progressive thinning of the cornea that gives rise to its protrusion. This results in irregular astigmatism and, in the late stages, corneal fibrosis with substantial visual impairment. It is usually diagnosed during puberty, with a very variable and unpredictable progression rate between patients, progressing for up to two decades following presentation.¹

Currently, non-surgical treatments for KC range from corrective glasses for the most incipient grades, to contact lenses for moderate and advanced stages.² There are, however, other therapeutic options for progressive KC, either involving the addition of tissue, as is the case with intrastromal ring implants, or photochemical treatments such as corneal collagen cross-linking (CXL) with riboflavin (RF) and ultraviolet A (UVA) radiation. The main objective of the latter treatment option is to halt or reduce the progression of ectasia, thereby avoiding or delaying the need for a corneal transplant.³

In 2003, Wollensak et al. introduced corneal CXL, which is one of the most promising procedures for halting progression of this disease, as it strengthens the cornea by increasing the cross-linking of collagen fibers, which in turn increases corneal rigidity, thereby reducing the morbidity of the disease and decreasing or delaying the need for a corneal transplant.³

Standard corneal cross-linking or epithelium-off CXL (epi-off CXL) requires removal of the corneal epithelium prior to impregnation of the cornea with RF and its irradiation for 30 min with ultraviolet A light (UV-A). Numerous studies have documented its safety and efficiency,⁴ and there have been publications reporting outcomes using this technique at more than 10 years of follow-up.⁵

However, this technique includes removal of the epithelium, which can result in postoperative pain and act as a potential source of complications (e.g., infectious keratitis, sterile infiltrates, and corneal haze).⁶

With the introduction of transepithelial corneal cross-linking (TE-CXL), removal of the corneal epithelium can be avoided and, therefore, also the associated inconveniences and complications. There has been an increasing number of published studies evaluating the therapeutic effects of TE-CXL. Recent studies have suggested that TE-CXL has ample potential to slow the progression of KC,⁷ and studies have compared both techniques in terms of the effects of the treatment.⁸⁻¹²

However, there have been few publications to date that compared both techniques taking into account the location of the cone. The initial corneal shape may be important for the final effect of the treatment since CXL increases the stability of the corneal structure and modifies the intrinsic biomechanical properties of corneal collagen.

Our work sought to compare both treatments after 3 years of follow-up, taking into account the patients' age and the location of the corneal ectasia.

Materials and methods

This was a comparative prospective study. Both the epi-off CXL and the TE-CXL collagen corneal cross-linking technique were evaluated. The patients were recruited at the Novovision Clinic (Madrid, Spain) and treated by the same medical team using the same surgical and post-surgical protocol. Before starting the study, the risks and benefits of the treatment were explained to the patients, and informed consent was obtained from all of the subjects. The patients were free to leave the study at any time. The study was conducted in compliance with good clinical practice guidelines, the institutional review board regulations, and the tenets of the Declaration of Helsinki revised in 2013.¹³ Moreover, the study was approved by the ethics committee of the Novovision Clinic.

I- Preoperative:

The following inclusion criteria were taken into account: all of the patients exhibited progressive KC according to topographic data (with progression defined as an increase of ≥ 1 diopter (D) in the manifest cylinder and/or an increase of ≥ 1 D in the maximum keratometry observed in three consecutive corneal topographies in the six months prior to the study⁸) that were grade I and II according to the Amsler-Krumeich classification (central keratometry less than 53 D, pachymetry greater than 400 μm , and myopia and/or astigmatism of 8 D or less¹) and all of the patients were older than 12 years of age. This study also excluded patients with collagen or autoimmune diseases, severe atopy, or other ocular diseases, as well as individuals who were pregnant or lactating.

Patients who used contact lenses were instructed to discontinue their use 7–10 days prior to treatment. The location of the cone was taken into account, including patients with central and paracentral KC.

Table 1 Variables and keratoconus index included in the study.

Visuals	Corneal aberrations	Previous and posterior structure	Corneal thickness
CDVA	Corneal aberrations: coma-like, spherical-like and HOAs	Astigmatism	Pachymetry at the apex and pachymetry at the thinnest point
Corneal densitometry		Keratometry: K-max and meanK	Corneal volume
		Corneal asphericity (Q6, Q8 and Q10)	
		R min	
		Maximum posterior elevation (6 mm)	
		Keratoconus index: ISV, IVA, KI, CKI, IHA, IHD	

CDVA: corrected distance visual acuity; HOAs: higher-order aberrations; K-max: maximal keratometry; mean K: mean keratometry; Q6, Q8, Q10: asphericity at 6, 8, and 10 mm; ISV: index of surface variance; IVA: index of vertical asymmetry; KI: keratoconus index; CKI: central keratoconus index; IHA: index of height asymmetry; IHD: index of height decentration; R min: minimum radius of curvature.

We classified the KC as being central if the distance between the point of least corneal thickness and the center of the cornea was 0.7 mm or less, while the KC was classified as paracentral if that distance was between 0.7 and 2.1 mm.¹⁴

Patients who met the inclusion criteria were assigned to one of the two treatment groups, i.e., the epi-off CXL or the TE-CXL group, in a consecutive manner starting with the TE-CXL until the required sample was reached. II- Intraoperative:

With both techniques, the same UVA emitter device, namely a CBM X-linker (CSO, Florence, Italy) was used with all of the patients.

With the epi-off CXL technique, the central 8 mm of corneal epithelium was removed with a scarifier. Drops of 0.1% RF solution were then instilled with 20% dextran (Ricrolin®, Florence, Italy) every 5 min for a total duration of 30 min to saturate the corneal stroma. Using a slit lamp, yellow-colored staining could then be seen throughout the corneal layer and in the anterior chamber. A UVA light source, at an intensity of 3 mW/cm² and a wavelength of 370 nm (corresponding to the maximum absorption of the RF) was then applied over the course of 30 min until a total radiation exposure of 5.4 J/cm² was achieved.^{3,4} During the treatment, the RF was instilled every 5 min and a topical anesthetic was administered every 15 min. At the end of the surgical procedure, a single drop of tobramycin and dexamethasone (Tobradex®, Barcelona, Spain) and a neutral therapeutic contact lens were applied.

For the TE-CXL technique, the procedure was performed in a similar manner as the CXL epi-off technique, although without removal of the corneal epithelium, using a TE-RF (Ricrolin TE®) composed of RF 0.1%, 15% dextran, trometamol, and ethylenediaminetetraacetic acid (EDTA). The remainder of the process was carried out in the same

manner, and there was no need for a therapeutic contact lens.

III- Postoperative:

As postoperative treatment we recommended Tobramycin/Dexamethasone 1 mg/mL+3 mg/mL eye drops (tobradex®, Barcelona, Spain) every 6 h for one week and then Fluorometholone 0.1% eye drops (FML®, Madrid Spain) for 1 month in a de-escalating dose.

The two treatment groups were compared over time (6, 12, 24, and 36 months) taking into account the age of the patients and the location of the KC (central or paracentral). In all of the follow-up visits, an ophthalmological examination was performed, including assessment of the corrected distance visual acuity (CDVA), topography, and corneal aberrometry. The data analyzed in this work were obtained using a Pentacam (Oculus, Wetzlar, Germany) corneal topographer.

The variables evaluated in this study were divided into three groups, namely the visual quality, the corneal structure, and the KC index visual variables, corneal aberrations, previous and posterior structure and corneal thickness (Table 1)

Statistical analysis

The statistical analysis was performed using SPSS Statistics 23 software (IBM, Chicago, Illinois, USA). A descriptive analysis was carried out for all of the study variables, thus yielding frequency tables for the categorical variables (gender, eye, etc.) and tables with the descriptors of the continuous variables, which are presented as means and the standard deviation, and ranges. In all cases, the Kolmogorov-Smirnov normality test and the homogeneity test were carried out to determine the statistical approach to be used in each case.

To calculate the sample size, the same procedure was followed as in the CXL study performed by Raiskup-Wolf et al.¹⁵ which was obtained by the difference between the expected average change of the maximum K after treatment (estimated at -1.46 D) and the acceptable average change of the maximum K value after treatment (estimated by Koller et al¹⁶ as +1 D). With this difference of -2.46 D, and taking into account a standard deviation of 3.76¹⁵ the sample size necessary for an alpha of 0.05 and a beta of 0.2 is 29 eyes in each group¹⁷ Taking into account a possible dropout rate during the study of 10%, the total number of eyes needed was estimated to be 32 per group.

With each variable, a repeated measures ANOVA (variance analysis) was performed to study the differences between both groups (epi-off CXL/TE-CXL) over time (6, 12, 24, and 36 months) according to the location of the KC cone (central or paracentral) and age as main effects, as well as all double interactions. A statistical significance of 0.05 was established ($p < 0.05$). The results are presented as means \pm the standard deviation.

Results

The study included 64 eyes from 46 patients with progressive Amsler-Krumeich grade I and II KC, of which 31 eyes were treated with epi-off CXL and 33 with TE-CXL, with a mean age of 19.90 ± 5.7 years (17.82–21.99 years) and 25.33 ± 6.8 years (22.92–27.75 years), respectively.

Table 2 shows the patient distribution according to the surgical technique, the degree of KC, and the location of the ectasia.

The baseline characteristics of each of the variables to be studied in both treatment groups and their degree of homogeneity are detailed in Table 3.

The groups were not homogeneous in terms of age or the maximum K value, as the patients in the group being treated with epi-off CXL tended to be younger and have more advanced KC. Since age is an important factor that needs to be taken into account with this pathology, it was included as a covariate in the statistical method.

After the collagen corneal CXL procedure, significant changes in the corrected distance visual acuity (CDVA) and asphericity at 6 mm (Q6) were found over time that depended on the location of the cone. The CDVA improved both for those with a central KC (mean of -0.2 log MAR) and with a paracentral KC (mean of -0.07 log MAR) (p -value < 0.05 ; one-way ANOVA for repeated measures). The asphericity at 6 mm improved for those with a central KC, (p -value < 0.05 ; one-way ANOVA for repeated measures), while it remained stable with a paracentral KC (Table 4)

Significant differences were found between both treatments over time in terms of the coma-like aberration, higher-order aberrations (HOAs), densitometry, maximum K (Fig. 1), asphericity at 8 mm and 10 mm (Q8, Q10), pachymetry at the apex, pachymetry at the thinnest point, index of surface variance (ISV), and the minimum radius of curvature (R min) (p -value < 0.05 ; one-way ANOVA for repeated measures). After epi-off CXL, there was improvement in the coma-like aberration, HOAs, Q8, Q10, and ISV values, while after TE-CXL, these variables remained stable. Additionally, the changes in densitometry and corneal

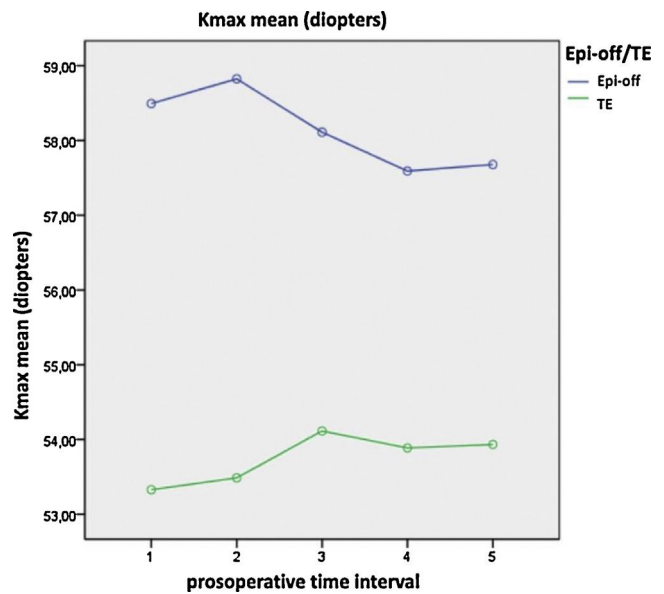


Fig. 1 Significant changes in maximum K over time depending on the treatment used (epi-off CXL and TE-CXL). 1- preoperative, 2- 6 months, 3-12 months, 4- 24 months and 5-36 months.

pachymetry were significant after epi-off CXL, remaining stable after TE-CXL, and the variables of maximum K and the anterior minimum radius remained stable with both treatments (Table 5).

We did not have any complications with any of the techniques.

Discussion

Since Wollesak introduced the crosslinking of corneal collagen (CXL) in the treatment of QC in 2003,³ it has been shown to be effective in slowing down or stopping the progression of QC.^{4,5} However, the removal of the corneal epithelium remains controversial.^{6,17,18} On the other hand, TE-CXL is developed to avoid the adverse effects caused by the removal of the corneal epithelium.⁷ And in recent years, several clinical trials have been designed to compare the therapeutic effects between the two methods.⁸⁻¹²

Our study sought to compare both treatments over a three-year period, taking into account the age of the patients and the location of the corneal ectasia.

One of the drawbacks of our study was the lack of homogeneity in the groups of patients treated with the different surgical techniques, since the baseline characteristics of patients treated with TE-CXL comprised less advanced KC than was the case for patients treated with epi-off CXL. Certain variables present clinically different values in the preoperative period. This is justified by the allocation criteria for each epi-off CXL or TE-CXL group. As this was not a clinical trial, the study was not randomized and it followed the protocol for the assigned allocation of the private clinic in which the study was conducted. As can be seen in the tables, the values of the variables that exhibited significant differences in the preoperative period were higher than those performed with epi-off CXL. This indicates a greater

Table 2 The number of eyes treated with CXL epi-off versus CXL TE according to the degree and the location of the KC.

Type of CXL	Grade I	Grade II	Total	Central KC	Paracentral KC
Epi-off CXL	17	14	31	13	18
TE CXL	23	10	33	6	27
Total	40	24	64	19	45
	p-value = 0.220			p-value = 0.038	

CXL: corneal crosslinking; KC: keratoconus.

Chi-square test results of Grade I/II between two groups of treatment, p-value = 0.220.

Chi-square test results of central/paracentral kc between two groups of treatment, p-value = 0.038.

Table 3 Baseline characteristics of the study groups.

Variables	epi-off CXL	TE CXL	p-value
Age, years (rank)	19.90 ± 5.7(17.82–21.99)	25.33 ± 6.8(22.92–24)	0.001*
CDVA (log MAR)	0.1635 ± 0.13	0.0981 ± 0.21	0.179
Coma-Like (μm)	3.27 ± 1.72	2.19 ± 1.49	0.090
Spherical-like (μm)	0.48 ± 0.42	0.47 ± 0.47	0.984
HOAs (μm)	3.5 ± 1.7	2.4 ± 1.3	0.005*
Corneal densitometry	27.95 ± 5.37	22.42 ± 3.41	0.001*
Astigmatism (D)	4.12 ± 2.4	3.13 ± 1.5	0.050
K-max (D)	56.65 ± 5.9	51.95 ± 5.7	0.020*
Mean K (D)	47.64 ± 3.2	45.49 ± 3	0.070
Q6	−0.99 ± 0.72	−0.56 ± 0.62	0.012*
Q8	−0.82 ± 0.36	−0.54 ± 0.34	0.020*
Q10	−0.70 ± 0.36	−0.60 ± 0.22	0.170
Maximum posterior elevation (μm)	54.39 ± 25.87	48.88 ± 30.39	0.439
Pachymetry at the apex (μm)	484.52 ± 32.47	499.18 ± 38.02	0.103
Pachymetry at the thinnest point (μm)	475.35 ± 33.73	483.79 ± 43.59	0.392
Corneal volume (mm ³)	58.13 ± 3.82	57.94 ± 3.66	0.838
ISV	91.26 ± 34.29	72.91 ± 37.31	0.045*
IVA	1.03 ± 0.56	0.82 ± 0.49	0.086
KI	1.25 ± 0.12	1.18 ± 0.11	0.012*
CKI	1.06 ± 0.04	1.04 ± 0.05	0.063
IHA	41.50 ± 28.08	23.12 ± 21.41	0.007*
IHD	0.11 ± 0.06	0.09 ± 0.06	0.125
R min (mm)	6.02 ± 0.63	6.56 ± 0.67	0.002*

CDVA: corrected distance visual acuity; HOAs: higher-order aberrations; K-max: maximal keratometry; mean K: mean keratometry; Q6, Q8, Q10: asphericity at 6 mm, 8 mm and 10 mm; ISV: index of surface variance; IVA: index of vertical asymmetry; KI: keratoconus index; CKI: central keratoconus index; IHA: index of height asymmetry; IHD: index of height decentration; R min: minimum radius of curvature.

* p < 0.05; one-way ANOVA for independent measure.

degree of development of keratoconus in those undergoing this procedure.

Age did not influence the variables studied, except for the index of height asymmetry (IHA).

Both of the surgical techniques resulted in stabilization of the CDVA during the 36-month follow-up, which is similar to the results obtained in a number of other studies,¹⁹ although most of the comparative studies to date have reported improvement with both techniques.^{8–12}

CDVA improved in patients with central and paracentral KC treated with corneal CXL, with significant differences between them over time, with a greater increase in central KC.

The two most significant indicators of improvement in vision after corneal CXL were the preoperative values of low CDVA ($\leq 20/40$) and high K-max values (≥ 55 D).^{1,8,20,21} In

the current study, the central KCs exhibited lower average values for the preoperative CDVA, with higher K-max values (0.25 ± 0.04 log MAR and 56.6 D) compared to paracentral KC (0.1 ± 0.2 log MAR and 53.84 D), which could explain these results. The greater improvement in the CDVA in the central cones is in accordance with what has been published by other authors,^{22,23} and this may be due to the fact that the central area is closer to the radiation of the CXL, so the intensity of radiation is higher than in the paracentral region, plus the depth does not appear to be homogeneous within the treatment area, exhibiting a decrease towards the periphery of the cornea.²⁴

The coma-like and HOA values remained stable after TE-CXL, while there was a significant improvement after epi-off CXL despite the fact that patients treated with epi-off CXL had a more advanced KC. This may be explained by a greater

Table 4 The values for the CDVA and Q6 after the corneal CXL taking into account the location of the cone over time.

Variable	Keratocons location	Preop	6m	12m	24m	36m	inter-group p-value	intra-group p-value**
CDVA (log mar)	Central KC	0.25 ± 0.04	0.16 ± 0.05	0.04 ± 0.05	0.06 ± 0.04	0.05 ± 0.04	0.001*	0.001*
	Paracentral KC		0.11 ± 0.03	0.09 ± 0.03	0.04 ± 0.03	0.03 ± 0.02		
Q6	Central KC	0.11 ± 0.02	-1.59 ± 0.20	-1.69 ± 0.20	-1.47 ± 0.18	-1.40 ± 0.18	0.04*	0.599
	Paracentral KC		-0.58 ± 0.13	-0.69 ± 0.13	-0.60 ± 0.11	-0.58 ± 0.12		
	KC							

CDVA: corrected distance visual acuity; Q6: asphericity at 6 mm; p: statistical change at month 36 compared with preoperative data; one-way ANOVA for repeated measures.

Inter-group p-value (preoperative inter-group difference: 36 months).

intra-group p-value ** (preoperative intra-group difference: 36 months).

degree of regularization of the corneal surface due to more compaction of the collagen fibers following this technique. The spherical aberration and coma values remained stable with both techniques in the comparative study by Rossi et al.²⁵ The random controlled trial by Stojanovic et al.²⁶ did find significant changes in HOAs during the 12-month follow-up in all of the groups and between them.

The densitometry readings remained stable after TE-CXL, while after epi-off CXL there was a significant increase after 6 months, going from an initial average of 27.6 ± 1.4–40.6 ± 3.2, only to decrease at each of the subsequent checkup examinations, with no significant change with respect to the preoperative values from 12 months to the end of the study. Similar results were obtained by Greenstein et al.⁶ The increases may be associated with the depth of CXL in the stroma, as well as with the amount of keratocyte loss, activated keratocytes, inflammation of the stroma due to changes in pressure, interactions of proteoglycans-collagen, hydration of glycosaminoglycans, and an increase in the diameter of collagen fibers of 12.2% (3.96 nm).²⁷

The K-max is an indicator of the stability of the KC after CXL. Progression of the KC is generally defined as an increase in the K-max of 1 D or more at 6,⁸ 12,²⁸ or 24²⁹ months. With both techniques, the K-max values remained stable, thus halting further KC progression and taking into account that the patients with more advanced KC were treated with epi-off CXL, which is similar to what was noted by Stojanovic et al.²⁶ and Cifariello et al.¹¹ Most of the studies to date have reported a decrease or stabilization of the K-max with both techniques.^{10,19,25} However, Kocak et al.³⁰ obtained an improvement in the K-max after epi-off CXL and a worsening after TE-CXL.

One simple method to quantitatively describe the corneal shape is the corneal asphericity. The Q6 values of the central KC became less negative and the Q8 and Q10 values became less negative after epi-off CXL in this study. Therefore, epi-off CXL regularized the corneal surface more than TE-CXL, and it also improved more in central KC than in paracentral KC. This improvement in the Q values following CXL may be due to compaction of the collagen fibers that renders the cornea surface more regular. Sedaghat et al.³¹ reported stabilization of corneal asphericity values following epi-off CXL after 12 months of follow-up.

The groups were homogeneous both in terms of pachymetry at the corneal apex and at the thinnest point, decreasing in the first few months and then increasing from 12 months to the end of the study following epi-off CXL while remaining stable after TE-CXL. This is similar to what has been found in a number of studies,⁶ although other publications,^{19,25} have reported stability with both techniques. The reduction in corneal thickness following epi-off CXL could be a consequence of several factors such as collagen fiber compaction, stromal dehydration, cell death due to apoptosis of keratocytes after exposure to UVA light, alterations in the scarring and the epithelial distribution, and its subsequent increase could be a consequence of the repopulation of keratocytes that takes place after the sixth month.³² Failure to find these thickness changes following TE-CXL could indicate less of a structural effect.⁸

Following epi-off CXL, the ISV improved significantly, while remaining stable following TE-CXL, with a statistically significant difference with both treatments over the time period that was studied. With both techniques, the previous minimum radius remained stable during the study period, although there was a significant difference with both techniques over time. Magli et al.¹⁹ observed a statistically significant decrease in the IHA with both techniques, without finding differences between them. Çerman et al.⁸ found a significant decrease in the ISV and IVA (vertical asymmetry index) with both treatments. The KI (KC index) decreased after epi-off CXL, while it remained stable after TE-CXL. The CKI (central KC index) remained stable in both groups. The IHA did not change after epi-off CXL, although it increased following TE-CXL. The IHD (index of height decentration) increased in both groups. Today, to assess the evolution of keratoconus without surgery, several indices could be used, such as the D index, the index for height symmetry or the keratoconus progression index (KPI), which have been shown to be effective.³³ Likewise, the analysis of topography and epithelial thickness could be of interest to assess the effects that the different types of CXL have on this corneal layer and their responsibility for the changes found after the different types of treatment.

In our study, no significant differences were found in terms of astigmatism, posterior elevation, or corneal volume.

Table 5 The values for coma-like, HOAs, densitometry, K-max, Q8, Q10, pachymetry at the apex, pachymetry at the thinnest point, ISV, and anterior minimum radius taking into account both techniques over time.

Variable	Type of CXL	preoperative	6m	12m	24m	36m	inter-group p-value	intra-group p-value **
Coma-like	Epi-off CXL	3.39 ± 0.38	3.16 ± 0.38	3.14 ± 0.37	2.99 ± 0.32	2.79 ± 0.29	0.038*	0.033*
	TE CXL							
HOAs	Epi-off CXL	1.35 ± 0.47	1.35 ± 0.47	1.22 ± 0.46	1.32 ± 0.4	1.41 ± 0.37	0.036*	1.000
	TE CXL	3.78 ± 0.37	3.54 ± 0.37	3.39 ± 0.35	3.24 ± 0.31	2.83 ± 0.27		
Densitometry	Epi-off CXL	2.04 ± 0.45	1.70 ± 0.45	1.64 ± 0.43	1.67 ± 0.39	1.75 ± 0.33	0.003*	1.000
	TE CXL	27.58 ± 1.41	40.60 ± 3.20	31.40 ± 1.59	28.63 ± 1.31	28.04 ± 2.11		
K-max	Epi-off CXL	23.27 ± 1.71	22.24 ± 3.89	22.29 ± 1.93	21.29 ± 1.38	20.02 ± 2.57	0.038*	1.000
	TE CXL	58.49 ± 1.52	58.82 ± 1.66	58.11 ± 1.72	57.59 ± 1.62	57.68 ± 1.62		
Q8	Epi-off CXL	53.33 ± 1.82	53.49 ± 1.99	54.11 ± 2.06	53.93 ± 1.94	53.93 ± 1.94	0.049*	1.000
	TE CXL	-0.91 ± 0.06	-0.96 ± 0.08	-0.86 ± 0.07	-0.83 ± 0.07	-0.76 ± 0.07		
		-0.76 ± 0.08	-0.81 ± 0.11	-0.77 ± 0.09	-0.75 ± 0.09	-0.79 ± 0.10		1.000

Table 5 (Continued)

Variable	Type of CXL	preoperative	6m	12m	24m	36m	inter-group p-value	intra-group p-value **
Q10	Epi-off CXL TE CXL	-0.77 ± 0.05	-0.8 ± 0.05	-0.78 ± 0.05	-0.75 ± 0.05	-0.64 ± 0.06		0.088
							0.049*	
Pachymetry at the apex	Epi-off CXL TE CXL	-0.68 ± 0.06 485.25 ± 7.42	-0.7 ± 0.06 461.29 ± 8.40	-0.75 ± 0.06 475.91 ± 8.41	-0.78 ± 0.07 479.53 ± 8.07	-0.71 ± 0.08 482.3 ± 8.95		1.000 1.000
							0.005*	
Pachymetry at the thinnest point	Epi-off CXL TE CXL	492.93 ± 10.16 476.35 ± 8.34	490.41 ± 11.49 449.34 ± 8.61	492.34 ± 11.51 463.41 ± 8.55	487.88 ± 11.05 461.72 ± 8.94	485.94 ± 12.25 468.7 ± 8.9		1.000 0.679
							0.003*	
ISV	Epi-off CXL TE CXL	481 ± 11.42	482.46 ± 11.79	481.72 ± 11.71	47,419 ± 12.25	47,479 ± 12.19		1.000
ISV	Epi-off CXL TE CXL	95.49 ± 8.07	94.99 ± 8.09	91.48 ± 7.79	89.68 ± 7.53	87.04 ± 7.46		0.035*
							0.049*	
R min	Epi-off CXL TE CXL	62.24 ± 11.05 5.82 ± 0.14	59.93 ± 11.08 5.8 ± 0.15	58.59 ± 10.67 5.87 ± 0.15	60.17 ± 10.31 5.92 ± 0.15	62.34 ± 10.21 5.93 ± 0.15		1.000 0.795
							0.05	
		6.41 ± 0.19	6.41 ± 0.2	6.37 ± 0.21	6.36 ± 0.2	6.37 ± 0.2		1.000

HOAs: higher-order aberrations; K-max: maximal keratometry; Q8, Q10: asphericity at 8 mm, 10 mm; ISV: index of surface variance; R min: minimum radius of curvature; P: statistical change at month 36 compared with preoperative data. One-way ANOVA for repeated measures.

Inter-group p-value (preoperative inter-group difference: 36 months).

Intra-group p-value ** (preoperative intra-group difference: 36 months).

Even though the most frequent postoperative complications after the epi-off CXL technique are infection,³⁴ persistent corneal edema³⁵ and the need for keratoplasty,³⁶ our study did not reveal a difference between the group treated with epi-off CXL and treatment with transepithelial CXL, as in other works.^{8,25} This may be due to the fact that patients were treated in the early stages of keratoconus and the sample size was not too big, which suggests that a larger number of subjects may be needed to be able to compare the rate of postoperative complications between CXL techniques

In conclusion, epi off-CXL was more effective from the point of view of the aberometric and morphological properties of the cornea although both techniques halted and stabilized the progression of KC, epi-off CXL was more effective. Additionally, following the corneal CXL technique, there was a greater degree of regularization of the corneal surface and, therefore, a greater degree of improvement in the visual acuity that was corrected much more in central KC than in paracentral KC.

Financial disclosure

None of the authors has a financial or proprietary interest in any material or method mentioned.

Conflict of interest

The authors declare that there is no conflict of interest.

References

- O'Brart DP, Kwong TQ, Patel P, McDonald RJ, O'Brart NA. Long-term follow-up of riboflavin/ultraviolet A (370 nm) corneal collagen cross-linking to halt the progression of keratoconus. *Br J Ophthalmol*. 2013;97:433–437.
- Fátima T, Acharya MC, Mathur U, Barua P. Demographic profile and visual rehabilitation of patients with keratoconus attending contact lens clinic at a tertiary eye care center. *Contact Lens Anterior Eye*. 2010;33:19–22.
- Wollensak G, Spoerl E, Seiler T. Riboflavin/ultraviolet-a-induced collagen crosslinking for the treatment of keratoconus. *Am J Ophthalmol*. 2003;135:620–627.
- Li W, Wang B. Efficacy and safety of transepithelial corneal collagen crosslinking surgery versus standard corneal collagen crosslinking surgery for keratoconus: A meta-analysis of randomized controlled trials. *BMC Ophthalmol*. 2017;17:262.
- Mazzotta C, Traversi C, Baiocchi S, et al. Corneal collagen cross-linking with riboflavin and ultraviolet A light for pediatric keratoconus: Ten-year results. *Cornea*. 2018;37:560–566.
- Greenstein SA, Fry KL, Bhatt J, Hersh PS. Natural history of corneal haze after collagen crosslinking for keratoconus and corneal ectasia: Scheimpflug and biomicroscopic analysis. *J Cataract Refract Surg*. 2010;36:2105–2114.
- Caporossi A, Mazzotta C, Paradiso AL, Baiocchi S, Marigliani D, Caporossi T. Transepithelial corneal collagen crosslinking for progressive keratoconus: 24-month clinical results. *J Cataract Refract Surg*. 2013;39:1157–1163.
- Çerman E, Toker E, Oxarslan Ozcan D. Transepithelial versus epithelium-off crosslinking in adults with progressive keratoconus. *J Cataract Refract Surg*. 2015;41:1416–1425.
- Soeters N, Wisse RPL, Godefrooij DA, Imhof SM, Tahzib NG. Transepithelial versus epithelium-off corneal crosslinking for the treatment of progressive keratoconus: A randomized controlled trial. *Am J Ophthalmol*. 2015;159:821–828.
- Rush SW, Rush RB. Epithelium-off versus transepithelial corneal crosslinking for progressive corneal ectasia: A randomised and controlled trial. *Br J Ophthalmol*. 2017;101:503–508.
- Cifariello F, Minicucci M, Di Renzo F, et al. Epi-off versus epi-on corneal collagen cross-linking in keratoconus patients: A comparative study through 2-year follow-up. *J Ophthalmol*. 2018;29:4947983.
- Wen D, Song B, Li Q, et al. Comparison of epithelium-off versus transepithelial corneal collagen cross-linking for keratoconus: A systematic review and meta-analysis. *Cornea*. 2018;37:1018–1024.
- World Medical Association. World Medical Association Declaration of Helsinki: Ethical principles for medical research involving human subjects. *Jama*. 2013;310:2191–2194.
- Alfonso JA, Lisa C, Fernández-Vega L, Poo A, Madrid D. Keratoconus classification based on clinical phenotypes. In: Del Buey MA, Peris C, eds. *Biomechanics and corneal architecture*. Barcelona. Elsevier: SECOR; 2014:165–184.
- Raiskup-Wolf F, Hoyer A, Spoerl E, Pillunat LE. Collagen crosslinking with riboflavin and ultraviolet-A light in keratoconus: Long-term results. *J Cataract Refract Surg*. 2008;34:796–801.
- Koller T, Mrochen M, Seiler T. Complication and failure rates after corneal crosslinking. *J Cataract Refract Surg*. 2009;35:1358–1362.
- Wittes J. Sample size calculations for randomized controlled trials. *Epidemiol Rev*. 2002;24:39–53.
- Koppen C, Wouters K, Mathysen D, Rozema J, Tassignon MJ. Refractive and topographic results of benzalkonium chloride-assisted transepithelial crosslinking. *J Cataract Refract Surg*. 2012;38:1000–1005.
- Magli A, Forte R, Tortori A, Capasso L, Marsico G, Piozzi E. Epithelium-off corneal collagen cross-linking versus transepithelial cross-linking for pediatric keratoconus. *Cornea*. 2013;32:597–601.
- Badawi AE, Abou Samra WA, El Ghafar AA. Predictive factors of the standard cross-linking outcomes in adult keratoconus: One-year follow-up. *J Ophthalmol*. 2017;2017:4109208.
- Kasai K, Kato N, Konomi K, Shinzawa M, Shimazaki J. Flattening effect of corneal cross-linking depends on the preoperative severity of keratoconus. *Medicine (Baltimore)*. 2017;96:e8160.
- Greenstein SA, Fry KL, Hersh PS. Effect of topographic cone location on outcomes of corneal collagen cross-linking for keratoconus and corneal ectasia. *J Refract Surg*. 2012;28:397–405.
- Tian M, Ma P, Zhou W, Feng J, Mu G. Outcomes of corneal crosslinking for central and paracentral keratoconus. *Medicine (Baltimore)*. 2017;96:e6247.
- Greenstein SA, Hers Ps. Characteristics influencing outcomes of corneal collagen crosslinking for keratoconus and ectasia: Implications for patient selection. *J Cataract Refract Surg*. 2013;39:1133–1140.
- Rossi S, Orrico A, Santamaria C, et al. Standard versus trans-epithelial collagen cross-linking in keratoconus patients suitable for standard collagen crosslinking. *Clin Ophthalmol*. 2015;18:503–509.
- Stojanovic A, Zhou W, Utheim TP. Corneal collagen cross-linking with and without epithelial removal: A contralateral study with 0.5% hypotonic riboflavin solution. *Biomed Res Int*. 2014;2014:619398.
- Mazzotta C, Balestrazzi A, Traversi C, et al. Treatment of progressive keratoconus by riboflavin-UVA-induced cross-linking of corneal collagen: Ultrastructural analysis by Heidelberg retinal tomograph II in vivo confocal microscopy in humans. *Cornea*. 2007;26:390–397.

28. Hersh PS, Greenstein SA, Fry KL. Corneal collagen crosslinking for keratoconus and corneal ectasia: One-year results. *J Cataract Refract Surg.* 2011;37:149–160.
29. Leccisotti A, Islam T. Transepithelial corneal collagen crosslinking in keratoconus. *J Refract Surg.* 2010;26:942–948.
30. Kocak I, Aydin A, Kaya F, Koc H. Comparison of transepithelial corneal collagen crosslinking with epithelium-off crosslinking in progressive keratoconus. *J Fr Ophtalmol.* 2014;37:371–376.
31. Sedaghat M, Bagheri M, Ghavami S, Bamdad S. Changes in corneal topography and biomechanical properties after collagen cross-linking for keratoconus: 1-year results. *Middle East Afr J Ophthalmol.* 2015;22:212–219.
32. Spoerl E, Mrochen M, Sliney D, Trokel S, Seiler T. Safety of UVA-riboflavin cross-linking of the cornea. *Cornea.* 2007;26:385–389.
33. Shajari M, Steinwender G, Herrmann K, et al. Evaluation of keratoconus progression. *Br J Ophthalmol.* 2019;103:551–557.
34. Abbouda A, Abicca I, Alio JL. Infectious keratitis following corneal crosslinking: A systematic review of reported cases: Management, visual outcome, and treatment proposed. *Semin Ophthalmol.* 2016;31:485–491.
35. Sharma A, Nottage JM, Mirchia K, Sharma R, Mohan K, Nirankari VS. Persistent conical edema after collagen crosslinking for keratoconus. *Am J Ophthalmol.* 2012;154:922–926.
36. Shalchi Z, Wang X, Nanavaty MA. Safety and efficacy of epithelium removal and transepithelial corneal collagen crosslinking for keratoconus. *Eye (Lond).* 2015;29:15–29.