



## CASE REPORT

# An atypical presentation of visual conversion disorder



Brian K. Foutch\*

University of the Incarnate Word, Rosenberg School of Optometry, United States

Received 30 October 2014; accepted 1 January 2015

Available online 3 March 2015

### KEYWORDS

Nonorganic vision loss;  
Visual conversion disorder;  
Vision loss;  
Malingering

**Abstract** Nonorganic vision loss accounts for up to 5% of patients and presents in two forms, malingering and visual conversion disorder (VCD). It is described a case of VCD in a new mother struggling both with her husband being deployed overseas and the recent death of her father. In addition, she had been evaluated for a concussion secondary to a motor vehicle accident three months prior. An inexpensive series of clinical tests were performed to rule out organic disease and obtained equivocal results. Some tests revealed intact vision in the affected eye while others supported a neurological cause for the vision loss. However, the patient quickly recovered normal visual acuity when encouraged to discuss situations that have been causing emotional stress. This almost immediate recovery of vision confirmed the diagnosis of VCD. This report should make primary eye care professionals more aware of visual conversion disorder and its clinical evaluation.

© 2014 Spanish General Council of Optometry. Published by Elsevier España, S.L.U. All rights reserved.

### PALABRAS CLAVE

Pérdida de visión no orgánica;  
Trastorno de conversión visual;  
Pérdida de visión;  
Trastorno facticio

### Presentación atípica del trastorno de conversión visual

**Resumen** La pérdida de la visión no orgánica afecta a cerca del 5% de los pacientes, y se presenta bajo dos formas: simulación y trastorno de conversión visual (VCD). Se describe un caso de VCD en una madre primípara que se esforzaba por superar cambios repentinos en su vida con su marido en el extranjero y la reciente muerte de su padre. Además, había sido examinada a causa de una conmoción secundaria a un accidente de tráfico hacía tres meses. Se le realizaron una serie de pruebas clínicas no asociadas a un alto coste para descartar la enfermedad orgánica, obteniendo resultados equívocos. Algunas pruebas mostraban una visión intacta en el ojo afectado, mientras otras respaldaban una causa neurológica para la pérdida de visión. Sin embargo, la paciente recuperó rápidamente la agudeza visual cuando le animé a comentar las situaciones

\* Correspondence to: University of the Incarnate Word, Rosenberg School of Optometry, 9725 Datapoint Drive, San Antonio, TX 78229, United States.

E-mail address: [foutch@uiwtx.edu](mailto:foutch@uiwtx.edu)

que le habían originado el estrés emocional. Esta recuperación de la visión casi inmediata confirmó el diagnóstico de VCD. Este caso clínico debería servir de concienciación a los profesionales de la atención visual primaria en lo referente al trastorno de conversión visual y de su evaluación clínica.

© 2014 Spanish General Council of Optometry. Publicado por Elsevier España, S.L.U. Todos los derechos reservados.

## Introduction

Nonorganic vision loss accounts for 1–5% of patients in ophthalmic practice and has two forms, malingering and visual conversion disorder (VCD).<sup>1</sup> Malingering patients exaggerate their symptoms for the purpose of a consciously desired end such as financial gain, also known as “California Syndrome”.<sup>2</sup> While VCD is much less common—with visual changes due to stress-induced psychological changes<sup>3</sup>—differentiating between the two can be difficult.<sup>4</sup>

I report a case of VCD in the spouse of a United States military member. She was dealing with the solo care of an infant and the recent death of her father while her husband was deployed overseas. Both the diagnosis and management of her condition are discussed.

## Case presentation

### Initial presentation

A 36-year-old Hispanic woman presented on referral for a “suddenly blind right eye.” She reported treatment three months prior for a concussion secondary to a car accident, but denied current headaches, eye pain or medication use.

Entering visual acuities were 20/400 OD, 20/25<sup>\*</sup> OS but improved to 20/50 OD with pinhole and binocular polarized testing (every other letter projected separately to the right and left eyes). Extraocular muscle (EOM) movements were smooth and unrestricted, and confrontation fields were full to finger count. Pupils were equal (4 mm), reactive to light, and negative for afferent pupillary defect (APD). She was emmetropic, but refractive testing did reveal sensitivity to instructions with a marked reduction in acuity OD without encouragement (20/400) compared to with encouragement (20/50).

Slit lamp findings were normal, and internal examination revealed healthy optic nerves and cup to disc ratios of 0.2H/0.2V. Maculae, vessels, and peripheral retinas all appeared healthy on dilation. A working diagnosis of atypical nonorganic vision loss OD was made, and the patient was instructed to return the next day for central 30° threshold visual field (VF) testing via automated perimetry.

### Follow-up examination #1

The grayscale VF results are shown in Fig. 1. VF was effectively blank OD with a dense nasal hemianopia OS. I repeated the VF OS with OD unoccluded as any improvement in visual

field OS would then be owed to intact visual function OD. There was only mild improvement.

Since the severity of the VF loss was inconsistent with the best visual acuity (20/50 OD), I performed a battery of tests (described by Fish and Foroozan)<sup>1</sup> to rule out intact vision. I occluded her right eye and projected a 20/50 Snellen letter while I bisected the left pupil with a 10Δ prism base. She reported diplopia, obviously monocular in nature. I moved the prism completely over the left pupil and removed the occluder from her right eye. The diplopia persisted, revealing intact vision OD. Placing the 10Δ prism base out over OD caused a refixation of both eyes which further revealed intact vision OD. I then placed a 15Δ base-up prism over her right eye, and she was able to walk around easily. A patient with intact vision in both eyes should struggle with such a large induced vertical diplopia.

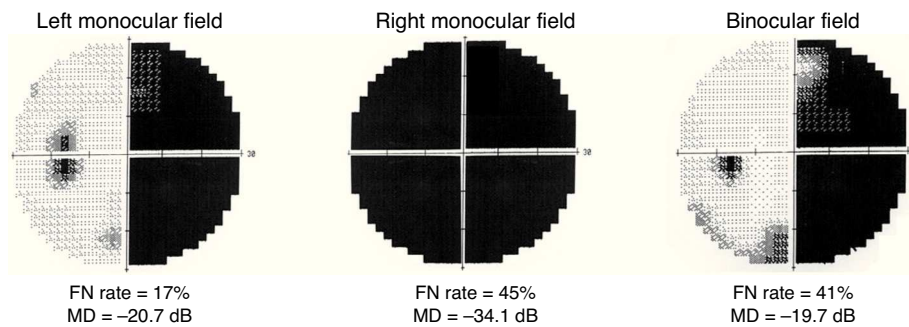
The support for a VCD diagnosis was equivocal, so I explained to her that I could not provide a medical explanation and planned to refer to her to neurology for imaging. I asked if there was any recent event in addition to the motor vehicle accident that she thought may have caused this loss of vision. She began crying and explained that her husband was deployed, she was struggling by herself at home with a nine-month-old infant, and that her father had just passed away in Puerto Rico. She did not know whether she would be able to attend the funeral. I reassured her and retested several minutes later, and her unaided distance visual acuity improved to 20/20 OD, OS. To best summarize this examination, “She cried for twenty minutes and was 20/20.”

She was diagnosed with VCD and scheduled for a repeat VF examination. I reassured her that the symptoms would improve and referred her for repeated neuroimaging and behavioral management. The neurology clinic deferred imaging based on normal pupil responses, visual acuity and post-concussion scans. I received no details of follow-up from behavioral management and ultimately lost this patient to follow-up.

## Discussion

Unilateral decreased visual acuity does occur without an APD in several conditions including: refractive error, amblyopia, lens or vitreous opacity, and macular lesion.<sup>1</sup> There was neither refractive error nor alternate amblyogenic factors in either eye. Along with the acute onset, these findings made amblyopia a highly unlikely cause of the vision loss. Media opacities and macular lesions were ruled out on funduscopy examination.

Hemianopias are relatively uncommon in VCD, occurring in only about 17% of cases.<sup>5</sup> When they do occur, the most



**Figure 1** Grayscale results of monocular and binocular 30 degree threshold visual field testing. Unlike most patterns seen in VCD, these results are optically possible. False negative (FN) rate and mean deviation (MD) are shown for each test.

frequent patterns are either a temporal hemianopia or blank field in the affected eye, full fields in the unaffected eye, and a complete hemianopia toward the affected side on testing with both eyes open.<sup>6</sup> Our patient's VF results were optically possible but did not fit either of these typical VCD patterns.

It has been suggested that automated perimetry is not useful based on the apparent ease with which malingerers can simulate certain types of neurological defects.<sup>1</sup> While this may be the case, this patient was clearly not malingering. The number of false negatives was greatly increased when the affected eye was involved (45% for OD, 41% for OU) when compared to testing the unaffected eye (17% for OS). This is consistent with the suggestion that optically treating the affected eye in nonorganic eye disease may undermine reassurance and delay recovery.<sup>1</sup> By drawing attention to the affected eye during automated testing, we may have exacerbated the symptoms and added useful information for our diagnosis.

It is important to acknowledge that the neurological work-up she had for the concussion may have served as a precursor to her current condition. Previous patient series have shown that 3–50% of all patients (26% in primary care settings) diagnosed with conversion disorder have concomitant neurological comorbidity.<sup>7</sup> Toone has forwarded unique interpretations for this,<sup>8</sup> and his two most widely accepted theories can be summarized by examples in our patient. First, the concussion may have simply provided a model for VCD; second, spending time during treatment for the concussion in medical environments could have “rewarded” or encouraged future illness.

The behavioral management referral is a vital portion of this patient's management, as psychiatric comorbidity is common.<sup>7</sup> Uncontrolled studies have shown that the majority of this comorbidity comes in the form of depression (38–50%) and anxiety disorders (10–16%), but at least one prospective controlled study found a fourfold increase in depression in conversion disorder subjects when compared with controls.<sup>9</sup>

Our final diagnosis of VCD was straightforward as normal visual acuity was quickly recovered by the tactful suggestion that there may be “behavioral” causes. In addition, our patient's symptoms met the abbreviated criteria for conversion disorder: (1) visual deficits that suggest a neurological cause, (2) symptoms did not appear to be intentionally produced, (3) symptoms could not be

explained by a medical condition, and (4) psychological factors were ultimately judged to be, at least in part, responsible for her vision loss.<sup>10</sup> Aiding in the diagnosis were her cooperative nature and indifference to lengthy testing.

## Funding

None declared.

## Conflicts of interest

The author has no conflicts of interest to declare.

## Acknowledgements

None declared.

## References

1. Fish RH, Foroozan R. Nonorganic visual disorders. In: Kline LB, Foroozan R, eds. *Neuro-ophthalmology review manual*. Thorofare, NJ: SLACK Inc.; 2013:231–243.
2. Keltner JL, May WN, Johnson CA, Post RB. The California syndrome functional visual complaints with potential economic impact. *Psychol Med*. 1983;92:427–435.
3. Vuilleumier P. Hysterical conversion and brain function. *Prog Brain Res*. 2005;150:309–329.
4. Rada RT, Meyer GG, Keltner R. Visual conversion reaction in children and adults. *J Nerv Ment Dis*. 1978;166:580–587.
5. Keane JR. Hysterical hemianopia: the ‘missing half’ field defect. *Arch Ophthalmol*. 1979;97:865–866.
6. Keane JR. Patterns of hysterical amblyopia. *Neurology*. 1998;51(October):1230–1231.
7. Crimlisk HL, Ron MA. Conversion hysteria: history, diagnostic issues, and clinical practice. *Cogn Neuropsychiatry*. 1999;4:165–180.
8. Toone BK. Disorders of hysterical conversion. In: Bass C, ed. *Somatisation: physical symptoms and psychological illness*. Oxford, UK: Blackwell; 1990:207–234.
9. Binzer M, Anderson PM, Kullgren G. Clinical characteristics of patients with motor disability due to conversion disorder. *J Neurol Neurosurg Psychiatry*. 1997;63:83–88.
10. American Psychiatric Association. *Diagnostic and statistical manual of mental disorders*. 5th ed. Washington, DC: American Psychiatric Association; 2013.